

11. HISTOLOGICAL INVESTIGATION OF VERY SMALL CREMATED BONE FRAGMENTS – OPTIONS AND LIMITATIONS

Birgit Grosskopf

*Johann-Friedrich-Blumenbach-Institut für Zoologie und Anthropologie, Abteilung für Historische Anthropologie und Humanökologie, Bürgerstraße 50, 37073 Göttingen
birgit.grosskopf@biologie.uni-goettingen.de*

<https://dx.doi.org/10.15496/publikation-69859>

KEYWORDS | cremation, histology, age estimation, animal bones, dental cementum

ABSTRACT

The anthropological analysis of cremated bone material originating from the archaeological context often poses a great challenge to the examiner due to the high degree of fragmentation, thermally induced shrinkage, and deformation. Histological methods have proven useful for determining the age at death in these osseous remains. Cross sections of long bones are used during the qualitative histological examination. This allows for an assessment of characteristics pertinent to this analysis including individual structural elements such as osteons, Haversian canals, the lamellar structure or resorption lacunae. Histological features characteristic for each age group are described. In addition, the implementation of tooth root cementum examinations for aging, in which annual rings are counted, is presented.

Animal bones are commonly found in cremations, e.g. through admixtures. In the case of very small diaphyseal fragments, morphological identification can often be very difficult. But a distinc-

tion between animal and human bones is usually possible based on the internal structure of the compact bones.

11.1 INTRODUCTION

Anthropological examinations conducted on burned bones are generally more difficult than on unburned bones due to various thermic induced changes incurred on them. Heavy fragmentation and incomplete state of preservation complicate diagnoses such as sex determination. In order to assess specific morphological features, for example, the sciatic notch or subpubic angle used in sexing skeletal remains, a certain minimum in size is necessary. Pelvic fragments characterized by large amounts of cancellous bone are seldom preserved in cremations. It is therefore necessary to assess small scale aspects of these structures. In this way, very small parts of the supra orbital ridge can be examined to ascertain whether the edge is sharp (female characteristic) or blunt (male).



Completeness with respect to the amount and representation of skeletal elements in the cremated remains also play a significant role in the accuracy of age estimation. In subadults, the size and wall thickness of long bones, dental development and epiphyseal closure deliver sufficient information for aging their remains. However, adult skeletons undergo only gradual modifications with age. In unburned skeletons, the pubic symphysis and auricular surface of the pelvis are examined to identify these changes. In addition, age-related degenerative changes seen on the vertebrae or large joints of the extremities as well as tooth wear can be assessed. The implementation of these diagnostic measures is often impeded in the examination of cremated remains not only because of fragmentation but primarily because of the incompleteness in representation of the skeleton. Skeletal elements with diagnostically important features such as the pelvis, vertebrae and epiphyses, which however are largely composed of cancellous bone tend to be underrepresented and tooth enamel commonly fractures away entirely due to the differing expansion coefficients between enamel and dentin. The morphological estimation of age at death in adult individuals is often reduced to an assessment of skull suture obliteration. Suture closure is not only characterized by a large span in individual variation (e.g. Szilvássy, 1988; Jackes, 2000) but the often very small cranial fragments exhibiting sutures cannot always be associated with a specific suture segment. However, this is a prerequisite for estimating age since, for example, there can be an approximately 30 year difference between the ectocranial obliteration of segment S2 of the sagittal suture and segment L2 of the lambdoidal suture. Both segments possess a fairly tortuous meander that could easily lead to possible confusion. As a result, age at death estimations in cremations are often made in broad categories like subadult and early or late adult.

11.2 HISTOLOGICAL INVESTIGATIONS

Because of this situation, it is advantageous to prepare histological thin sections to help increase



Figure 1: View of a Biodur block with three embedded cremated bone fragments.

the accuracy of age estimations (e.g. Cuijpers and Schutkowski, 1993; Grosskopf, 2004). This method is benefited by the fact that it can be performed on small fragments.

The proportions of different bone microstructures such as lamellae, osteons or resorption lacunae change throughout a lifetime. Numerous quantitative methods for estimating age at death have been developed which focus on the different microstructures as seen in histological sections (for an overview see Robling and Stout, 2000). In 1976, Herrmann had already shown that the fundamental microstructure of bone remains unchanged following cremation. However, because the shrinkage factor cannot be quantified, quantitative methods should not be used for estimating age at death in burned bones (Grosskopf, 2004). Experimental cremation of bones from individuals of known age shows that histologically estimated age and the actual age are in accordance (Hummel and Schutkowski, 1993).

When possible, the bone segment chosen for histological age estimations should preferably come from the femur, but not at the Linea aspera (Grosskopf, 2004). Viewed in cross section, microstructures are not evenly distributed, as indicated by Drusini (1996) and also personal experience shows. It is therefore important that not just one small femur fragment be examined, but multiple (at least three to four). These can be embed-

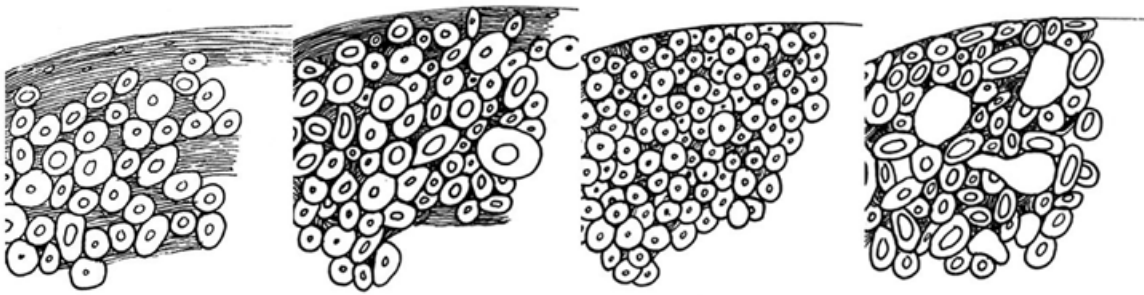


Figure 2: Schematic illustration showing age-dependent changes to the microstructure in a bone cross section. Left to right: age class juvenile, adult, mature, senile, from Grosskopf (2004).

ded together in an epoxy (Fig. 1), allowing them all to be sawed in a single step. The best medium for fixation of bones and teeth has proven to be Biodur epoxy made by Biodur Products GmbH (Heidelberg). Subjecting the sample to a vacuum ensures that the epoxy infiltrates the interstitial spaces. After the epoxy has dried, thin sections are made using a Leitz water-cooled saw microtome. Usable sections can also be prepared with the help of a sanding technique (Schultz, 1988; Nováček, 2012). Maat et al. (2001) describe a simplified method which does not require sophisticated laboratory equipment and can also be used to produce adequate sections. Thin section thickness should be less than 80-100 μm , and based on material quality and transparency, it is advisable to make much thinner sections. In order to prevent very thin sections from tearing away during sawing, a cover slip can be glued directly over the cutting surface of the embedded bone fragment.

11.3 AGE-DEPENDENT CHANGES TO BONE MICROSTRUCTURE

A qualitative assessment for age estimations and categorization into specific age groups is based on the following characteristics as seen in a bone cross section. A description of fundamental bone structure and individual components can be found in every histology textbook.

Basic age-related changes are illustrated in Fig. 2.

The bones of subadult individuals are comprised primarily of lamellae and relatively few osteons. Secondary osteons and intermediate lamellae appear as singular structures. The number of osteons increases with age. In the age class „adult“ (20-40 years) a certain amount of lamellar structures are still observable.

While the areas containing lamellar structures in the age class “early adult” are spread throughout the cross (Fig. 3), their presence in the middle adult age class is restricted to the periosteal region and the unbroken, cortical lamellae continue to decrease into late adult age. Still, they appear in this region even though osteons are not seen at the outer margin. A lamellar structure is also present endosteal, however, it is more difficult to evaluate than the continuous layer of cortical lamellae at the periosteum because of the transition area to the cancellous bone surface. The size and shape of osteons in the age class “adult” is irregular as is the size of the Haversian canals. This and the density changes from the early adult to the late adult age class generally making a distinction into early, middle or late adult possible. The age class “mature” (40-60 years) is characterized by densely packed osteons that exhibit a similarity in size and shape (Fig. 4). In the age class “early mature” some remnants of the outer cortical lamellae are still recognizable, while the age classes middle and late adult show the presence of osteons up to the outer edge. One of the main changes observable in the late mature age class is the formation of large resorption lacunae at the endosteal area. They are characterized by com-




Figure 3: Bone cross section of an early adult individual showing lamellar structures at the inner and periosteal areas (the latter is continuous) (scale: 500 μm).

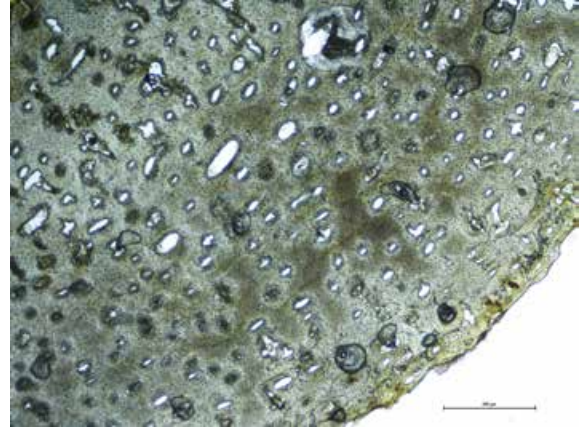


Figure 4: Bone cross section of an individual in the middle mature age class. Osteons are densely packed and the osteons reach all the way to the periosteal margin (scale: 500 μm).

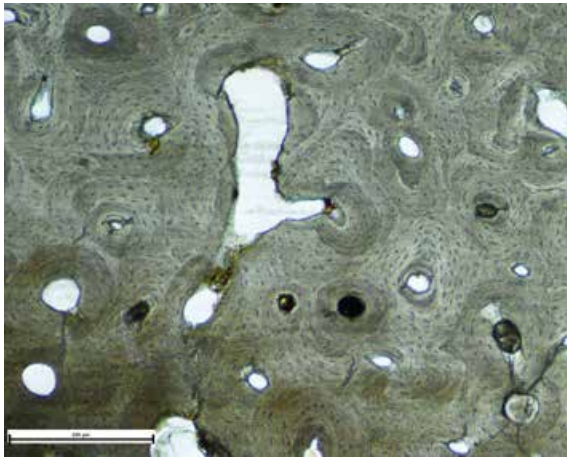


Figure 5: Expanded resorption lacunae (scale: 250 μm).

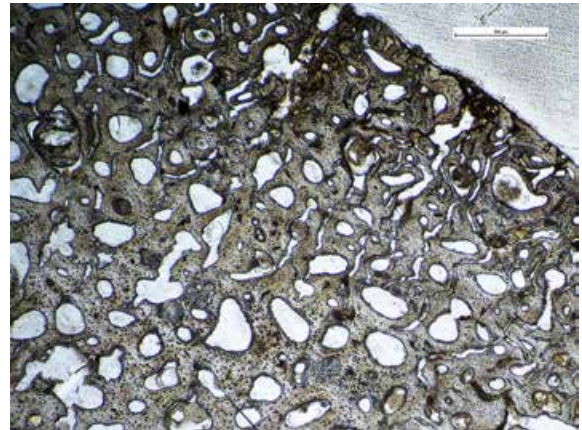


Figure 6: Numerous resorption lacunae in a bone cross section from an individual in the senilis age class (scale: 500 μm).

paratively irregular surfaces, which make them easy to differentiate from the Haversian canals (Fig. 5). The histological picture of an individual from the age class „senilis“ is characterized by numerous resorption lacunae spread throughout the entire bone cross section and shows irregularly shaped osteons most of which have relatively large Haversian canals (Fig. 6). The older the individual, the less dense the structure becomes. This loosely packed structure is sometimes even identifiable with the naked eye at freshly broken bone ends. However, caution should be taken not to confuse resorption lacunae with small tears caused by the heat. Confirmation using a light microscope at high magnification is therefore advisable. Bone cross sections from individuals with osteoporosis can exhibit similarities with the

age class senilis, since the same fundamental change of increased reduction of bone substance coupled with reduced formation is taking place. For this reason, as is the practice for all anthropological assessments of age or sex, a reliance on a single method should be avoided and all features available should be taken into consideration when possible. Particularly with respect to the fact that the biological age of an individual can be heavily influenced by various endogenous and exogenous factors.

11.4 TOOTH CEMENTUM ANNULATION

Appositional rings in tooth cementum can be counted in order to narrow down the actual




Figure 7: Appositional rings in the cementum layer of a premolar tooth belonging to a 57 +/-2.3 year old individual (cremation from Cottbus).

chronological age of an individual (Großkopf, 1989; Großkopf, 1990; Grosskopf and Hummel, 1992; Grosskopf and McGlynn, 2011). However, compared with unburned tooth roots, those deriving from cremations often possess a grainy quality in their optical appearance (Fig. 7). Therefore, as many slices per tooth root as possible should be prepared to ensure the greatest number of areas for counting. In the event that the tooth root mainly has opaque areas and no other roots are available for testing, then under certain circumstances only a minimum age estimation can be given. This is also necessary when the tooth from which the root originates cannot be specifically identified. As a result, the age of eruption is unknown and these years cannot be added to the number of rings counted, which is necessary to acquire the age estimation. In this case the earliest age of eruption for a tooth is added. In a molar root this would be the age of eruption for the first molar.

The great amount of time and effort required by this method makes it less attractive in its use as a standard method for large numbers of cremations. When the histological picture is characterized by a loose microstructure, yet the macroscopic assessment indicates a younger age at death, then osteoporosis could be the causative factor (see above). In this case, estimating age at death can be aided by employing the tooth cementum annulation method.

11.5 IDENTIFYING ANIMAL BONE

Animal bone fragments are often comingled with cremation burials and usually represent meat or



Figure 8: Sheep bone above and a red deer bone below, left is unburned and cremated at the right.

symbolic offerings that were burned together with the dead. The animals bones often exhibit lower burning temperatures than the human remains (Wahl, 1988). Even though most of the animal bones have been shown to stem from pigs (Wahl and Kokabi, 1988), a detailed archaeozoological examination should nonetheless be conducted. Information can be won to species, amounts of meat, preferences to anatomical parts (whether rich in meat or not), and correlation between sex and slaughter age (Kunter, 1994; Wahl, 2001; Wahl and Kokabi, 1988).

With the exception of phalanges from bears and pigs, most parts of epiphyses are readily identifiable as human or animal since they possess clearly different morphological features (Wahl, 2001). Animal bone diaphyses fragments are sometimes discernable in cross section alone or based upon their wall thickness combined with the cross section. Another criteria used is the bone's surface, because animal bones tend to have markedly smoother surfaces than seen in humans (Fig. 8 above). In addition, an assessment of the endosteal surface can be helpful since it is usually

much smoother than in human long bones (Fig. 8). Unfortunately, the smaller the fragment, the more difficult it becomes to examine the structure of these surfaces. It is not always possible to assess whether the surface is actually smoother or chalky and must be rubbed with the fingers to make this judgment. Chalky surfaces are generated at temperatures of ca. 700-800°C through the conversion of apatite crystals (Herrmann, 1988; Wahl, 2001). Temperatures can vary dramatically within a funeral pyre depending on how it is constructed, the wood used, and oxygen availability, and can all lead to a heterogeneous degree of bone cremation. In rare cases animal bones can be distinguished by an unusual breakage pattern that is sometimes combined with engraved surfaces (Grosskopf, 2013). Dried bones react to heat differently than fresh bones and exhibit straighter rather than parabolic fracture lines (e.g. Binford, 1963; Buikstra and Swegle, 1989; Herrmann, 1972; Ubelaker and Scammel, 1992). When the morphological determination of an animal bone is not possible or uncertain, then a histological cross section can be prepared to view the internal microscopic structures. Many animal species exhibit plexiform microscopic structures (Fig. 9). As the animal's age increases, this plexiform structure can be replaced by osteon bone (Herrmann et al., 2007; Robbins and Gray, 2011). Haversian canal diameter is markedly larger than in animals (Tab.

1) allowing for a measurable distinction. However, shrinkage caused by high temperatures must be taken into consideration when examining cremated bones. Therefore measuring the diameters alone is insufficient and it is advisable to compare a histological thin section of the animal in question with a section taken from cremated human bone. This allows for a more accurate assessment of size differences in Haversian canals.

11.6 EXAMINATIONS USING A BINOCULAR LIGHT MICROSCOPE

If the examiner has profound experience with the assessment of histological slides of bone cross sections, then a determination of animal or human bone can also be made using a conventional binocular microscope. If the bone edge is soiled with sediment, a new edge should be made. If this is not possible because the bone fragment is too small or the bone is too massive for a piece to be broken off, then the bone can be sawed. Following this, it should be cleaned in an ultrasonic bath to remove all sawdust residues. If a plexiform structure is observable, then an identification is easy. However, if osteon bone is present, then it is advisable to make a direct comparison with human bone under the binocular microscope to better assess the size and distribution of the Hav-




Figure 9: Plexiform structures in a cross section of burned bone. Wild boar at left, sheep at right (scale 500µm).

	MIN OSTEON	MAX OSTEON	MIN HAVERSIAN CANAL	MAX HAVERSIAN CANAL	AUTHOR
Human	277	352	58	76	Cattaneo et al. 1999
Human	174	281	33	50	Dittmann 2003
Human	244	508	56	74	Robbins & Gray 2011
Horse	158	205	26	33	Dittmann 2003
Horse	183	223	240	54	Mori et al. 2003
Cow	79	117	9	22	Mori et al. 2003
Cow	212	157	18	23	Dittmann 2003
Deer	67	143	17	29	Robbins & Gray 2011
Elk	108	157	14	30	Robbins & Gray 2011

Table 1: Osteon and Haversian canal diameters in unburned bones

ersian canals. For the experienced observer, this saves time and energy and allows for the identification of even very small diaphyses fragments that otherwise show no specific characteristics for animal bones.

Because of the positive experiences made in examining bone microstructure using conventional binocular microscopes, especially with respect to the morphological and histological estimation of age at death, an additional examination of the microscopic structures themselves is possible, leading to excellent results.

Successful assessment is exemplified in the determination of whether osteons reach the periosteal margin or if cortical lamellae are at the periosteal edge (Fig. 10 and 11). Loosely organized structures showing numerous large resorption canals are also readily observable. Classification of the bone into an age group adult, mature, and senilis is possible with the help of a binocular microscope under high magnification. Conducting blind tests with bone fragments versus histological thin sections showed that those observers highly experienced in microscopy were able to narrow down the actual age estimation and that there were no discrepancies between the histological examination and that using the binocular microscope. This procedure was successfully implemented, for example, in the examination of the Roman cremation cemetery Kaiseraugst „Im Sager“ (the final paper is in preparation by Amman et al.). Over 500 individual cre-

mation burials were recovered there. However, the finances available for that project did not allow for the preparation of histological thin sections for all of the sometimes sparingly small amounts of burial remains. As a result, sections of broken edges were examined by Cornelia Alder and the author with the help of a light microscope. Afterwards, histological sections made from the same bones were examined in a blind test. With only a few exceptions in which the surfaces or microscopic structures did not permit an assessment using the light microscope, there was a very good agreement between the age estimations made on the broken edges and those based on histological slides.

This type of examination is only possible when the person conducting the investigation has a great deal of experience in the histological determination of age at death in burned and unburned bones. The stereomicroscopic examination should not replace the histological assessment. It should only be used in cases where an age estimation would otherwise be impossible. Imaizumi (2015) recently described the option of using micro-computed tomography (micro-CT) for examining microscopic bone structures. This offers a possible alternative in archaeological finds in which invasive methods are not permitted. However, considering the numerous small fragments available in cremated burials and the work involved in preparing histological sections, this method is not recommended here.




Figure 10: Broken edge section from cremation burial Polch 72, in which a clear lamellar area without Haversian canals is visible, resulting in an age estimation of late adult.

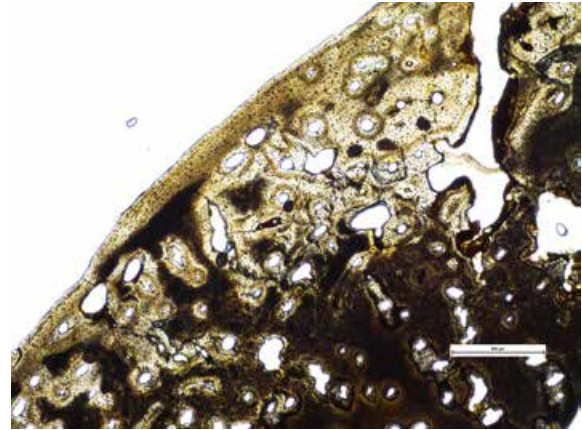


Figure 11: Histological cross section from cremation burial Polch 72, with recognizable continuous cortical lamellae and large, irregular Haversian canals typical for the age class late adult.

11.7 CONCLUSIONS

Histological examinations show great potential in the examination of cremations. They can be conducted on highly fragmented material, allowing for relatively accurate individual age at death estimations. Estimating age at death in cremated material is not limited to an assessment of epiphyseal closure or skull suture obliteration, although some authors continue to maintain this in the current literature (e.g. Piga et al., 2015). The analysis of tooth root cementum is shown to be an important tool in narrowing down estimations of age at death. Discerning between human and animal bone is possible even with small diaphyseal fragments lacking any characteristic features, simply based upon differences in their microscopic structures. In addition to the methods presented here, histological examinations can also provide valuable insight in the assessment of pathological changes (e.g. Nováček, 2012). When possible, histological analysis should always be employed in order to realize the full potential of this analytic method.

REFERENCES

- BINFORD, L.R.**, 1963. An Analysis of Cremations from Three Michigan Sites. *The Wisconsin Archeologist* 44, 98-110.
- BUIKSTRA, J.E.**, Swegle, M., 1989. Bone Modification Due to Burning: Experimental Evidence, in: Bonnichsen, R. (Eds.), *Bone modification*. Orono, pp. 247-258.
- CATTANEO, C.**, DiMartino, S., Scali, S., Craig, O.E., Grandi, M., Sokol, R.J., 1999. Determining the human origin of fragments of burnt bone: a comparative study of histological, immunological and DNA techniques. *Forensic Sci Int* 102, 181-191.
- CUJJPERS, A.G.F.M.**, Schutkowski, H., 1993. Histological age determination of the cremated human bones from the urnfields of Deventer t' Bramelt and Markelo Friezenberg. *Helinium* 33, 99-107.
- DITTMANN, K.**, 2003. Histomorphometrische Untersuchung der Knochenmikrostruktur von Primaten und Haustieren mit dem Ziel der Speziesidentifikation unter Berücksichtigung von Domestikationseffekten. *Anthropol Anz* 61, 175-188.
- DRUSINI, A.G.**, 1996. Sampling Location in Cortical Bone Histology. *Am J Phys Anthropol* 100, 609-610.
- GROSSKOPF, B.**, 1989. Incremental lines in prehistoric cremated teeth: A technical note. *Zeitschrift für Morphologie und Anthropologie* 77, 309-311.
- GROSSKOPF, B.**, 1990. Individualaltersbestimmung mit Hilfe von Zuwachsringen im Ze-

- ment bodengelagerter Zähne. *Zeitschrift für Rechtsmedizin* 103, 351-359.
- GROSSKOPF, B.,** Hummel, S., 1992. Altersdiagnose an Leichenbränden: Beobachtungen an Zuwachsringen im Zahnzement. *Archäologisches Korrespondenzblatt* 22, 567-569.
- GROSSKOPF, B.,** 2004. Leichenbrand – Biologisches und kulturhistorisches Quellenmaterial zur Rekonstruktion vor- und frühgeschichtlicher Population und ihrer Funeralpraktiken. Ph.D. dissertation, Universität Leipzig, Leipzig.
- GROSSKOPF, B.,** McGlynn, G., 2011. Age diagnosis based on incremental lines in dental cementum: A critical reflection. *Anthropologischer Anzeiger / Journal of Biological and Clinical Anthropology* 68, 275-289.
- GROSSKOPF, B.,** 2013. Anthropologische Befunde von Brandbestattungen der römischen Nekropole von Haltern, Kreis Recklinghausen, in: Berke, S., Mattern, T. (Eds.), *Römische Gräber augusteischer und tiberischer Zeit im Westen des Imperiums*. Harrasowitz Verlag Wiesbaden, pp. 162-177.
- HERRMANN, B.,** 1972. Das Combe Capelle-Skelett. *Ausgrabungen in Berlin* 3, 7-69.
- HERRMANN, B.,** 1976. Experimentelle und theoretische Beiträge zur Leichenbranduntersuchung. *Homo* 27, 114-118.
- HERRMANN, B.,** 1988. Behandlung von Leichenbrand, in: Knussmann R. (Eds.), *Anthropologie: Handbuch der vergleichenden Biologie des Menschen*. 4 Fischer Stuttgart/New York, pp. 576-585.
- HERRMANN, B.,** Grosskopf, B., Fehren-Schmitz, L., Schoon, R., 2007. Knochen als Spurenläger, in: Herrmann, B., Saternus, K.S. (Eds.), *Biologische Spurenkunde: Bd. I: Kriminalbiologie*. Springer Heidelberg, pp. 115-144.
- HUMMEL, S.,** Schutkowski, H., 1993. Approaches to the Histological Age Determination of Cremated Human Remains, in: Grupe, G., Garland, N. (Eds.), *Histology of ancient human bone: Methods and Diagnosis – Palaeohistology Workshop*. Springer Berlin, pp. 111-123.
- IMAIZUMI, K.,** 2015. Forensic investigation of burnt human remains. *Research and Reports in Forensic Medical Sciences* 5, 67-74.
- JACKES, M.,** 2000. Building the Bases for Paleodemographic Analysis: Adult Age Determination, in: Katzenberg, M.A., Saunders, S.R. (Eds.), *Biological Anthropology of the Human Skeleton*, pp. 417-466.
- KUNTER, M.,** 1994. Quantitative Zusammenhänge zwischen Alter, Geschlecht und Tierknochenbeigaben bei prähistorischen Bestattungen, in: Kokabi, M., Wahl, J. (Eds.), *Beiträge zur Archäozoologie und Prähistorischen Anthropologie*. Landesdenkmalamt Baden-Württemberg Stuttgart, pp. 57-63.
- MAAT, G.,** Bos, R.v.d., Aarents, M.J., 2001. Manual Preparation of Ground Sections for the Microscopy of Natural Bone Tissue: Update and Modification of Frost's 'Rapid Manual Method'. *Int Journal of Osteoarchaeology* 11, 366-374.
- MORI, R.,** Kodaka, T., Sano, T., Yamagishi, N., Asari, M., Naito, Y., 2003. Comparative Histology of the Lamellar Bone between Young Calves and Foals. *Cells Tissues Organs* 175, 43-50.
- NOVÁČEK, J.,** 2012. Möglichkeiten und Grenzen der mikroskopischen Leichenbranduntersuchung. Ph.D. dissertation, Universität Hildesheim, Hildesheim.
- PIGA, G.,** Guirguis, M., Allue, E., 2015. Funerary rituals and ideologies in the Phoenician-Punic necropolis of Monte Sirai (Carbonia, Sardinia, Italy), in: Thompson, T. (Eds.), *The Archaeology of Cremation: Burned Human Remains in Funerary Studies*. Studies in Funerary Archaeology, Oxford Philadelphia, Oxbow Books 8[5], 97-121.
- ROBBINS, G.,** Gray, K., 2011. What Remains: Species Identification and Bone Histology, in: Dixon, K.J., Schablitsky, J.M. and Novak, S.A. (Eds.), *An Archaeology of Desperation: Exploring the Donner Party's Alder Creek Camp*. Norman University of Oklahoma Press, pp. 157-177.
- ROBLING, A.G.,** Stout, S.D., 2000. Histomorphometry of Human Cortical Bone: Applicati-

- ons To Age Estimation, in: Katzenberg, M.A., Saunders, S.R. (Eds.), *Biological Anthropology of the Human Skeleton*. Wiley-Liss New York, pp. 187-213.
- SCHULTZ, M.**, 1988. Methoden der Licht- und Elektronenmikroskopie, in: Knussmann, R. (Eds.), *Anthropologie: Handbuch der vergleichenden Biologie des Menschen 1*. Fischer Verlag Stuttgart, pp. 698-730.
- SZILVÁSSY, J.**, 1988. Altersdiagnose am Skelett, in: Knussmann, R. (Eds.), *Anthropologie: Handbuch der vergleichenden Biologie des Menschen 1*. Fischer Verlag Stuttgart, pp. 421-443.
- UBELAKER, D.H.**, Scammel, H., 1992. Burning Questions, in: Ubelaker, D.H., Scammel, H. (Eds.), *Bones: a forensic detective's casebook*. HarperCollins New York, pp. 140-148.
- WAHL, J.**, 1988. Süderbrarup: Ein Gräberfeld der römischen Kaiserzeit und Völkerwanderungszeit in Angeln. II. Anthropologische Untersuchungen. Offa-Bücher [Neue Folge 64] Neumünster, 9-139.
- WAHL, J.**, 2001. Bemerkungen zur kritischen Beurteilung von Brandknochen. *Beitr. z. Archäozool. u. Prähist. Anthrop.* 3, 157-167.
- WAHL, J.**, Kokabi, M., 1988. Tierknochen, in: Wahl, J., Kokabi, M. (Eds.), *Das römische Gräberfeld von Stettfeld I: Osteologische Untersuchung der Knochenreste aus dem Gräberfeld*. Landesdenkmalamt Baden-Württemberg Stuttgart, pp. 225-284.

ACKNOWLEDGEMENTS

I warmly thank G. McGlynn for translating the text into English.